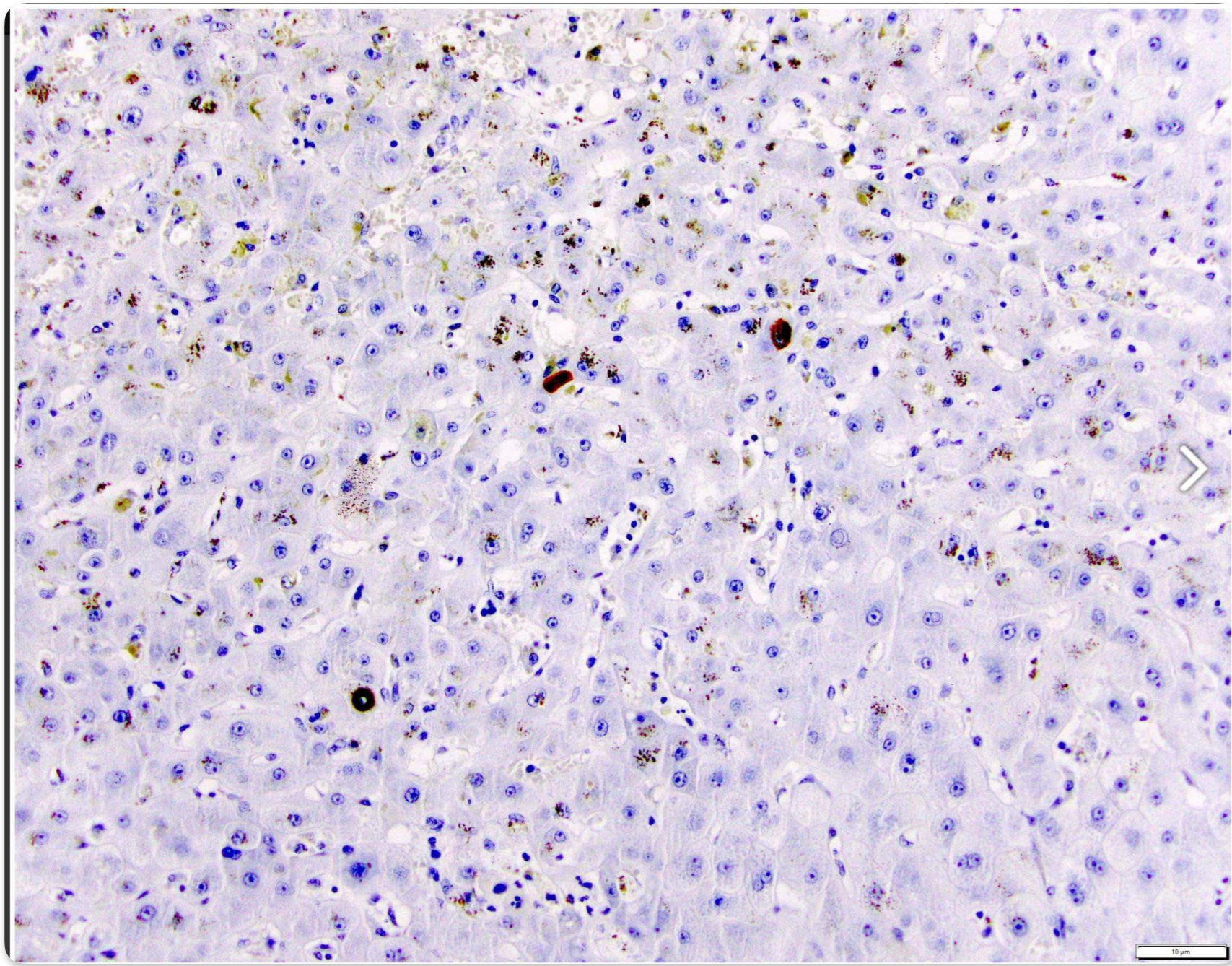
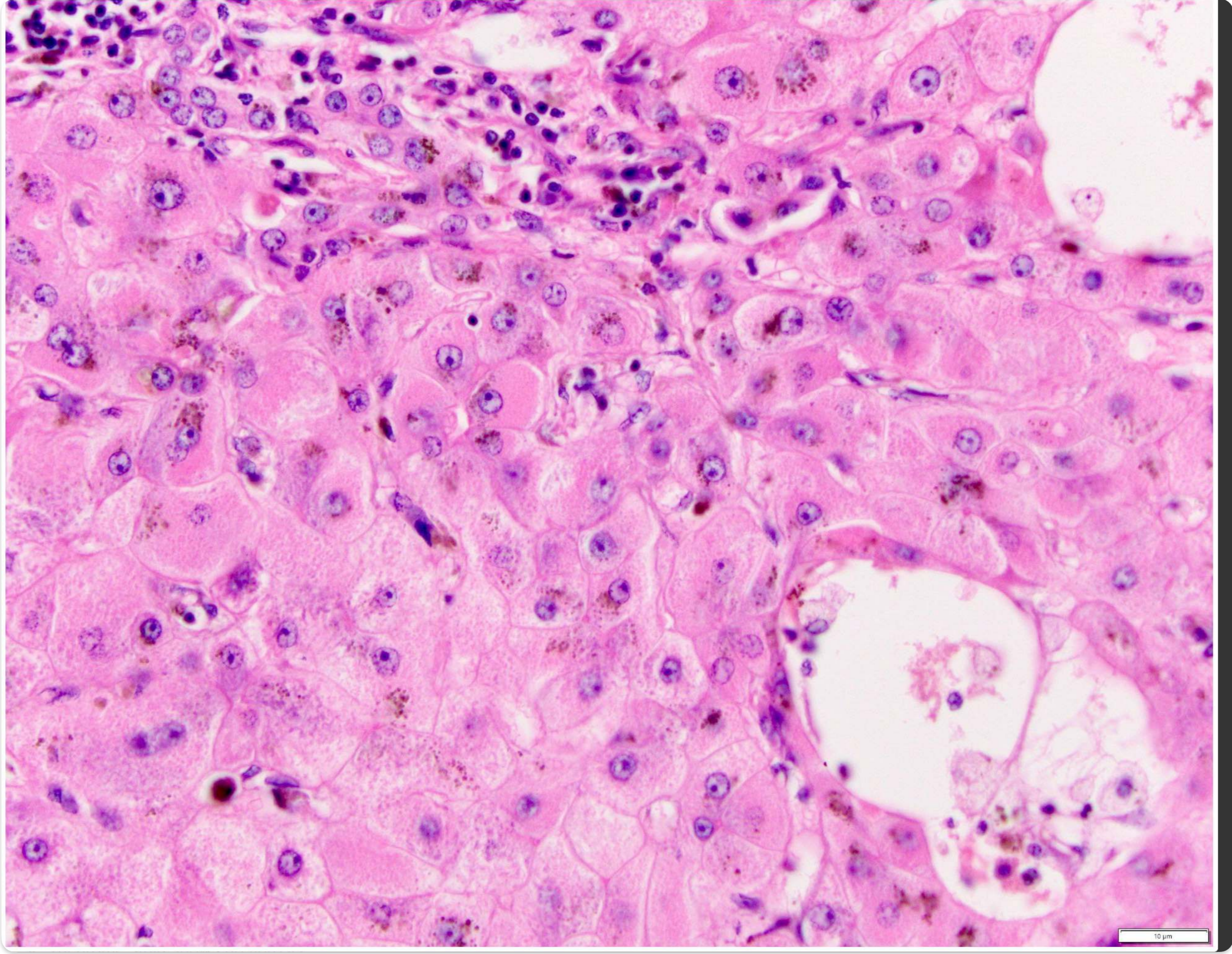
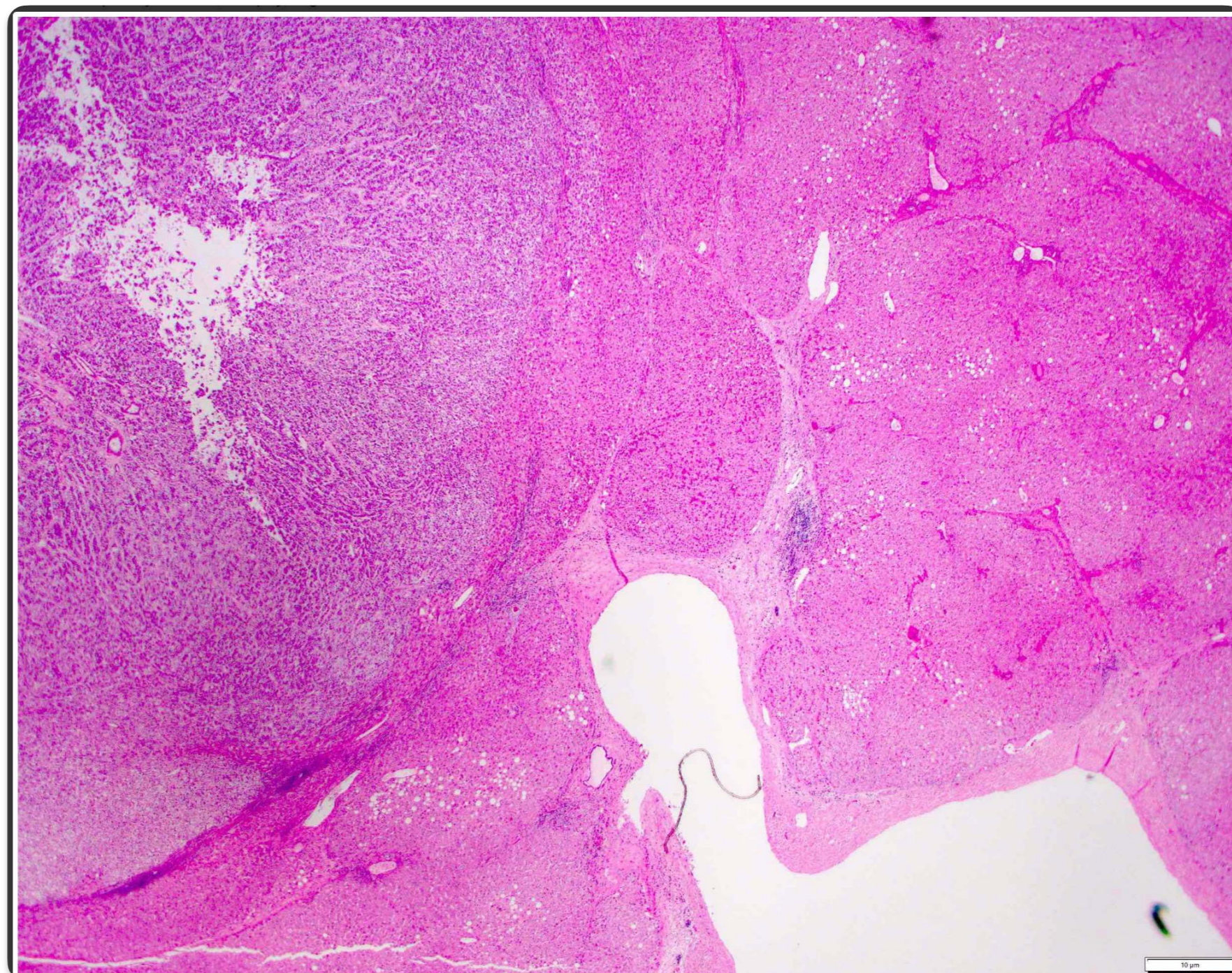


Ground glass hepatocyte in a patient with chronic hepatitis B infection.
Contributed by Monika Vyas, M.D.



HBsAg inclusions in the hepatocyte cytoplasm highlighted by HBsAg immunohistochemical stain.
Contributed by Monika Vyas, M.D



Hepatocellular carcinoma (top left) arising in a background of cirrhosis secondary to chronic hepatitis B infection.
Contributed by Monika Vyas, M.D